
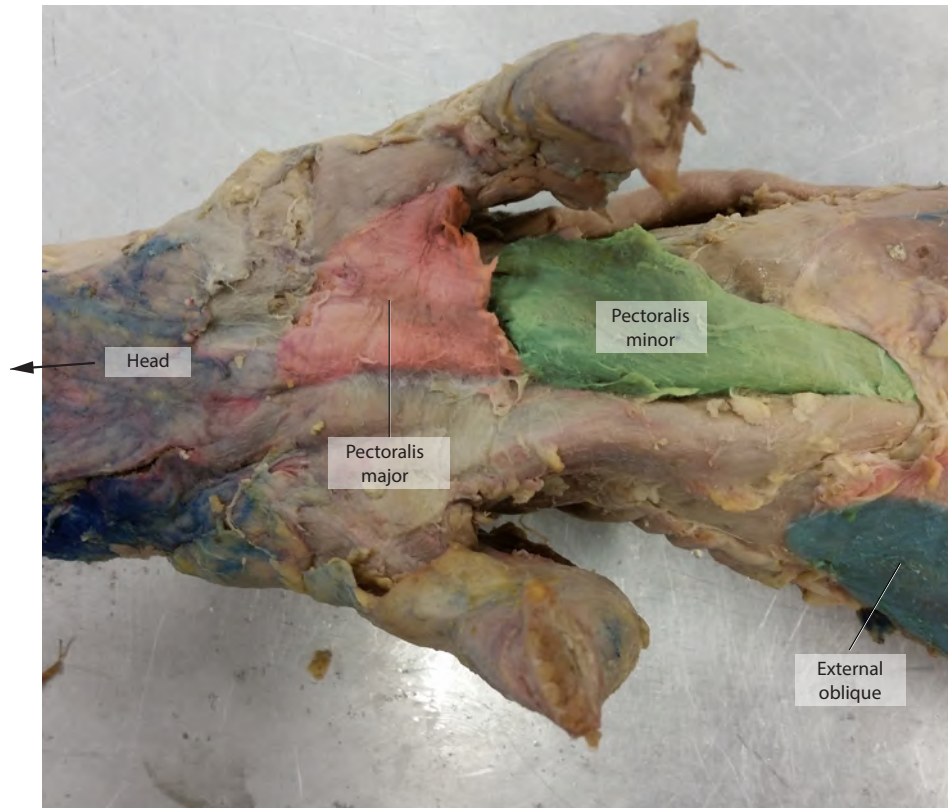


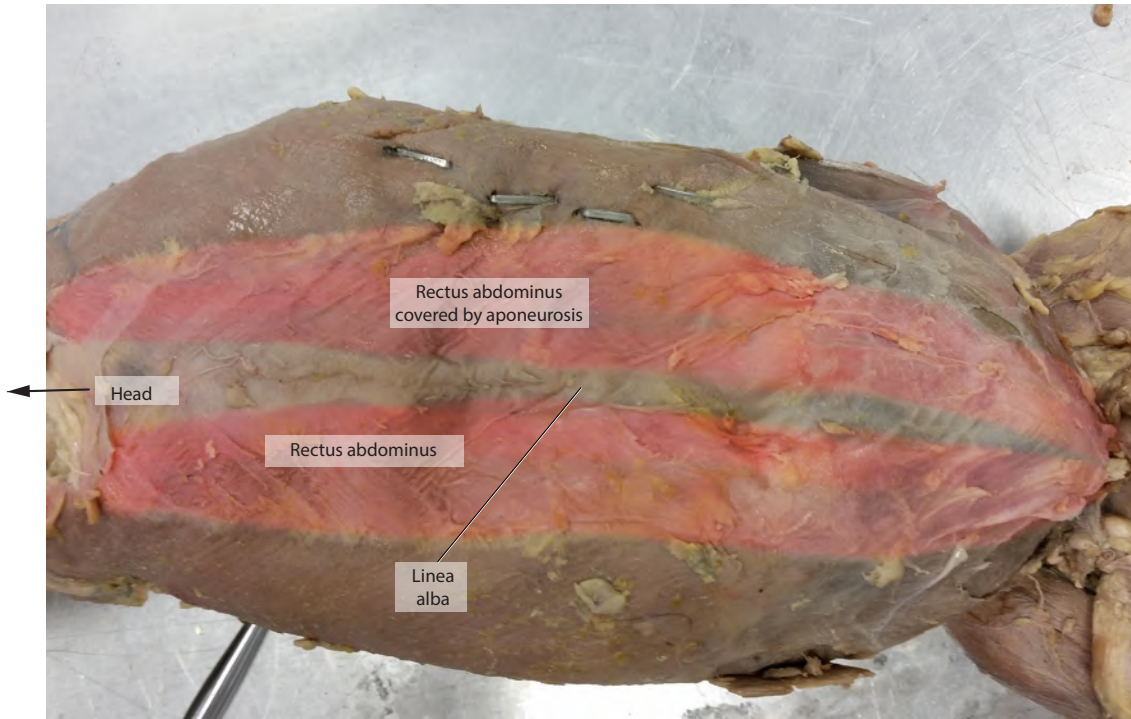
Ventral neck



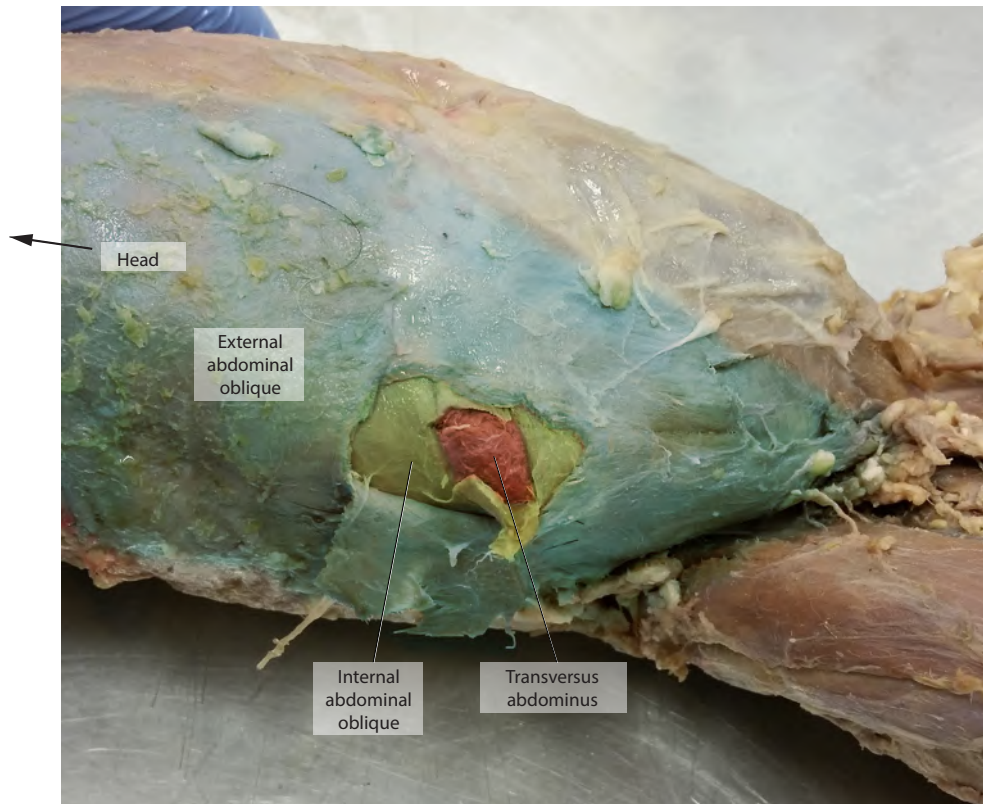
Ventral view



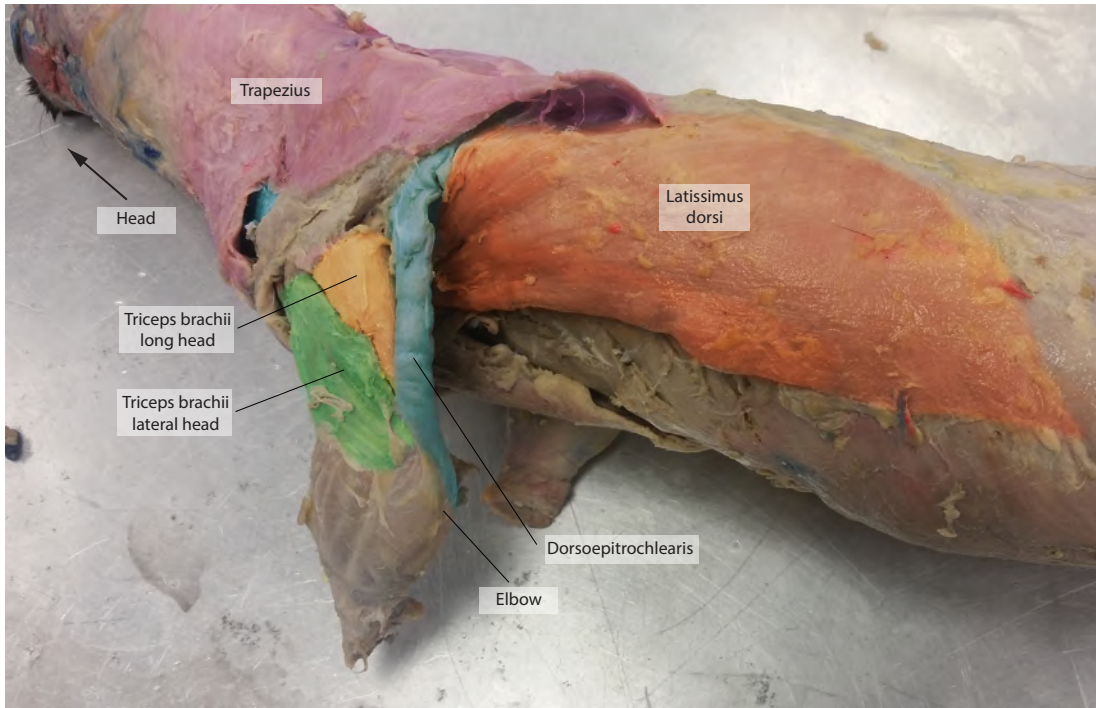
Ventral view



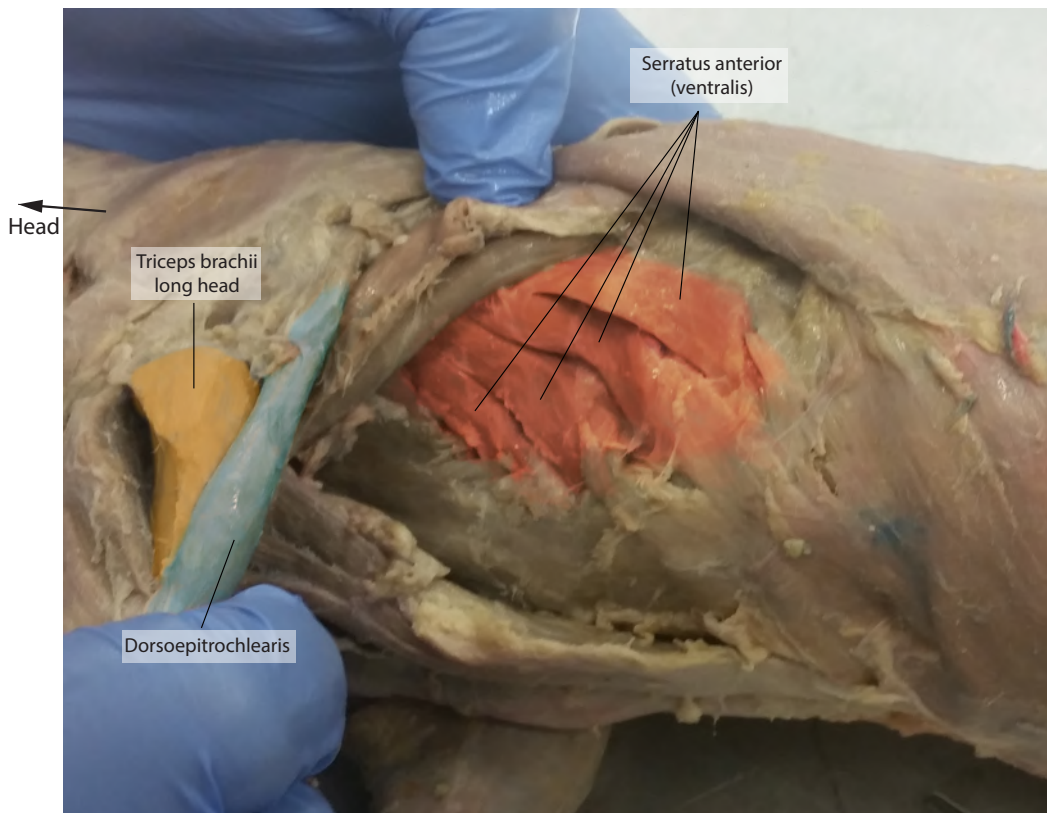
Ventral view



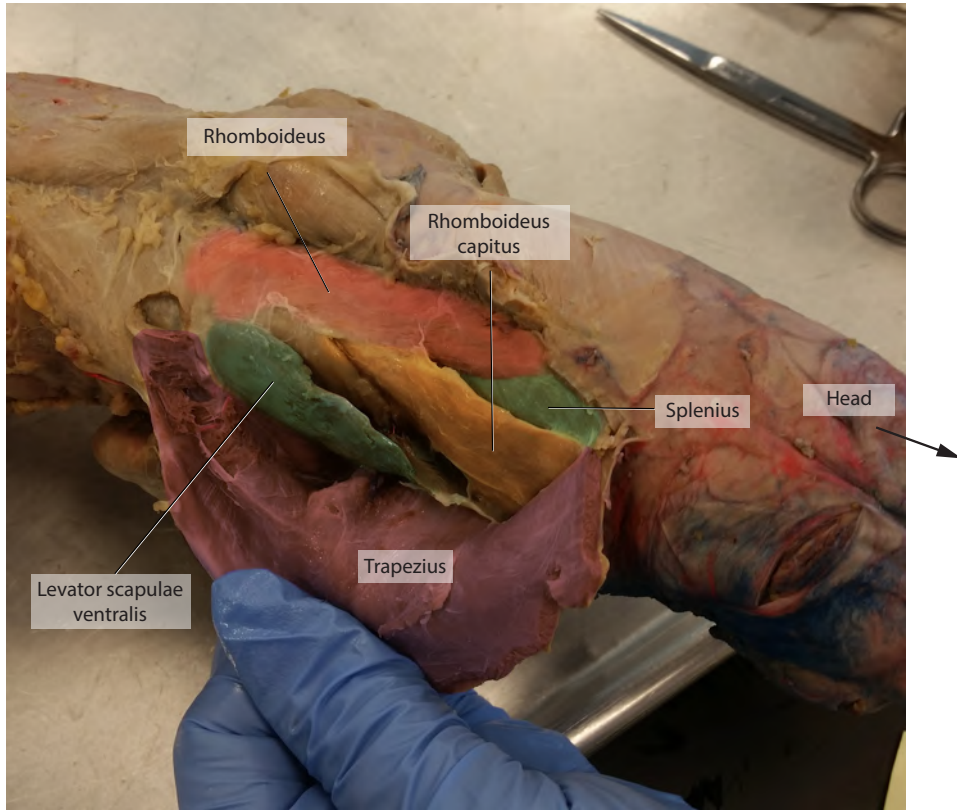
Left lateral view



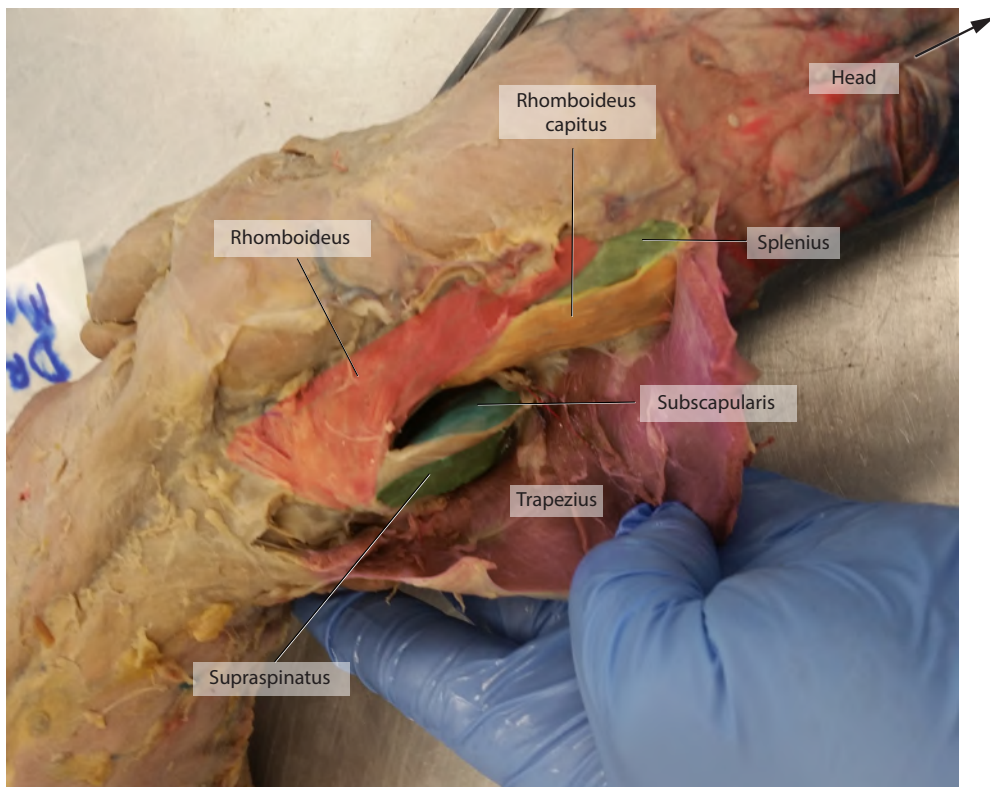
Left lateral view with arm pulled cranially and abducted slightly



Dorsal view



Dorsal trunk view



Dorsal trunk view

